

***SUBCHRONIC TOXICITY STUDY OF UREA MOLASSES MINERAL
BLOCK IN GOAT KIDS***

S. P. Tiwari, Angan Roy, Samiran Mondal¹ and M. K. Gendley

Department of Animal Nutrition, ¹Department of Veterinary Pathology, College of Veterinary Science and Animal Husbandry, Anjora, Durg- 491001, Chhattisgarh, India

anganroy@gmail.com

ABSTRACT

This experiment was to evaluate the effects of urea molasses mineral block (UMMB) supplementation on subchronic toxicity in indigenous goat kids. Twenty growing goat kids were randomly assigned to receive *ad libitum* rice straw and berseem hay (*Trifolium alexandrinum L.*) (40:60). Group I was fed concentrate mixture (0.1 kg/d). Group II was supplemented with UMMB (0.2kg/d). The experiment lasted for 90 days. There was significant ($p<0.05$) decrease in serum sodium (60.68mEq/L), increase in serum potassium (34.50 mEq/L) and increase in activity of Aspartate aminotransferase (340.42U/L) and Alanine aminotransferase (164.96 U/L) which were observed in kids of group II in comparison to the control (group I). On histopathological examination mild degenerative changes in kidney of group II with congestion in intertubular vessel, granular cytoplasm of the epithelial cells in proximal convoluted tubules (PCT) and distal convoluted tubules (DCT), necrosis and swelling of the epithelial cells, congestion of vessels and cloudy swelling was observed in PCT and DCT. Albuminous mass was also present in tubule. On histopathological observation of liver of kids of group II edema in liver parenchyma and proliferation of fibrous tissue in periportal area was observed.

Key Words: congestion • edema • liver • kidney • UMMB

INTRODUCTION

The rumen microbiota (bacteria and protozoa) are capable of converting nonprotein nitrogen compounds to protein. Urea has been used in ruminant rations for many years. It is generally recommended at a level of approximately 3% of the concentrate part of the ration or about 1% of the total ration. Urea molasses mineral blocks (UMMB) are licking blocks containing urea, molasses, minerals and other multinutrients. The feeding of blocks is a convenient and inexpensive method for providing a range of nutrients required by both the rumen microbes and the animal, which may be deficient in the diet. The main justification of using the blocks depends on their convenience for packing, storage, transport and ease of feeding. Overfeeding of UMMB may cause toxicity to animals due to its urea content. Toxicity of urea depends upon a rapid hydrolysis of urea by microbial urease to ammonia and carbon dioxide. The hydrolysis of urea may reach a peak in 30 minutes to 2 hours after its administration (**Rekib and Sadku, 1968**). The released ammonia is ideally utilized by rumen microbiota. However, when it is produced in excess, it passes through the epithelial cells of the rumen into portal vascular system. In the liver, ammonia is converted to urea and nonessential amino acids. However, a high concentration of ammonia, which may be produced in the rumen four times more rapidly than can be utilized (**Bloomfield et al., 1960**), that may cause toxicosis. A great controversy in the mechanism of urea toxicity still exists. The severity and extent of lesions vary on the basis of dose – response relationship (**Hooper, 1972**). In urea toxicity, there may be no characteristic lesions (**Clarke and Clarke, 1967**). However **Buck et al., 1973** reported a generalized congestion of the organs especially kidney and liver. These organs may suffer to a great extent of degenerative changes. On the paucity of the above pathological conditions the present study deals with sub chronic UMMB toxicosis in kids with measurement of certain blood biochemical parameters, serum enzymes and histopathological observations.

MATERIALS & METHODS

Animals: Twenty non-descript healthy goat kids of 3-5 months age were taken for the study. Animals were housed in well ventilated shed with facilities for individual feeding under hygienic and uniform management conditions. All kids were sprayed with Butox (Delltalmetrin, Hoeschst Rousse, Vet India) @ 3 ml/L of water at weekly interval for three weeks before the start of experiment to control the ectoparasites (Ticks, Mites and Flies), if any. The goat kids were randomly allocated on body weight basis to 2 groups of 10 animals each. All kids were dewormed by Albendazole (Albendos, 2.5% w/v Albendazole suspension, Dosch Pharmaceuticals Pvt. Ltd., Mumbai, India) @ 5 mg/kg body weight orally. The elimination of parasitic infection was confirmed by faecal examination. All kids were ear tagged. Five complete diets were prepared. The details are given in Table 1. The diets were fortified with mineral mixture (1%), salt

VETRINARY & DISEASES

(0.5%) and vitamin premix @ 20g/qfeed). All kids were fed diet *ad lib* which constituted of chopped rice straw and berseem hay followed by weighed amount of concentrate mixture. The blocks were given to be licked at rate 200 g by kids daily in the specified group at 09.00 am. Feeding was continued for 90 days. Composition of urea molasses mineral blocks are given in Table 2. The feed ingredients were analyzed for proximate components (AOAC, 1995), fiber components (Van Soest *et al.*, 1991), Ca, P (Fiske and Subba Rao, 1925) and trace elements (Cu, Co, Mn, Zn, Fe, Mo) by Atomic Absorption Spectrophotometer (Electronics Corporation of India Ltd. AAS 4141). The blood was collected from jugular vein puncture at the end of the experiment (90th day). Serum samples were analyzed for serum sodium, potassium, chloride, AST and ALT in Spectrophotometer (Erma Inc. of Tokyo, Japan, AE-11 M) and U.V. Spectrophotometer (Safas of Monaco, 4606) by using diagnostic kits (Bayer Autopk biochemistry kits - Baroda, Span Diagnostics Ltd. – Sachin, Lab-care Diagnostics Pvt. Ltd.- Sarigam) as per the methods recommended by manufacturer. All animals of each group were utilized for histological examination. Representative samples of liver and kidney were collected from the identical sites and histological slides were prepared and stained by Haematoxylin and Eosin method (Singh and Sulochona, 1997). The data were analyzed by Complete Randomize Design (Snedecor and Cochran, 1989).

Table 1: Dietary schedule of kids under different groups

Particulars/Treatment	T ₁	T ₂
Kids	4	4
Rice straw: berseem hay (40:60)	<i>Ad lib</i>	<i>Ad lib</i>
Concentrate mixture (g/d)	100	-
Urea Molasses Mineral Block (UMMB) (g/d)	-	200

Table 2: Composition of Urea Molasses Mineral Block

Ingredient	Parts (kg)
Molasses	40
Deoiled rice Bran	22
Urea	8
Soybean cake (deoiled)	16
Lime	6
Dicalcium phosphate	5
Mineral mixture	3
Total	100

Table 3 Chemical composition of diet (% DM basis)

Diet	CP	CF	EE	Ash	AIA	NFE	NDF	ADF	Hemi Cellulose	Cellulose	Lignin	Silica
Basal Diet	11.82	31.8	2.5	16.09	8.32	37.79	55.36	42.54	12.83	29.39	9.42	3.76
UMMB	35.85	3.88	0.23	20.99	2.12	39.04	29.12	11.90	17.22	10.41	8.10	3.90
Concentrate mixture	19.96	2.62	1.13	5.66	0.57	70.63	-	-	-	-	-	-

Table 4 Fiber components and mineral composition of diet (% DM basis)

Diet	Hemi Cellulose	Cellulose	Lignin	Silica	Ca	P	Fe (ppm)	Cu (ppm)	Co (ppm)	Mo (ppm)	Zn (ppm)	Mn (ppm)
Basal Diet	12.83	29.39	9.42	3.76	10.29	0.77	2287.00	98.60	38.60	634.60	221.00	323.00
UMMB	17.22	10.41	8.10	3.90	12.28	4.95	353.25	104.67	33.52	62.52	69.02	104.60
Concentrate mixture	-	-	-	-	1.21	0.35	91.02	11.27	0.24	2.67	21.25	17.17

VETRINARY & DISEASES

RESULTS

The chemical composition of the diet is presented in Table 3 and the fiber component and mineral composition of the diet is given in Table 4. There was significant decrease in serum sodium, increase in serum potassium and increase in activity of AST and ALT (Table 5) observed in kids of group T₂ in comparison to the control (T₁). No histopathological changes were observed in kidney (Fig. 1) and liver (Fig. 2) in kids of group T₁. On histopathological examination, mild degenerative changes in kidney of group T₂ with observed congestion in intertubular vessel (Fig. 3). Granular cytoplasm of the epithelial cells in PCT and DCT (Fig. 3) and cloudy swelling was observed in PCT and DCT (Fig. 4). Albuminous mass was also presented in tubule (Fig. 4). Necrosis and swelling of the epithelial cells and congestion of vessels was observed in the kidney of kid of group T₂. On histopathological observation of kid's liver of group T₂, oedema in liver parenchyma (Fig. 5) and proliferation of fibrous tissue in periportal area were observed (Fig. 6).

Table 5. Effect of subchronic toxicity of UMMB on serum minerals and serum enzymes level of kids

Parameters	Treatment	
	T ₁	T ₂
Sodium (mEq/L)	77.26±3.19 ^a	60.68±1.43 ^b
Potassium (mEq/L)	21.00±1.00 ^b	34.50±0.50 ^a
Chloride (mEq/L)	67.00±7.00	73.00±3.00
AST (U/L)	136.98±4.23 ^b	340.42±8.73 ^a
ALT (U/L)	57.15±1.52 ^b	164.96±1.66 ^a

Superscripts are read row wise for comparison of mean. Different superscripts differ significantly (P< 0.05).

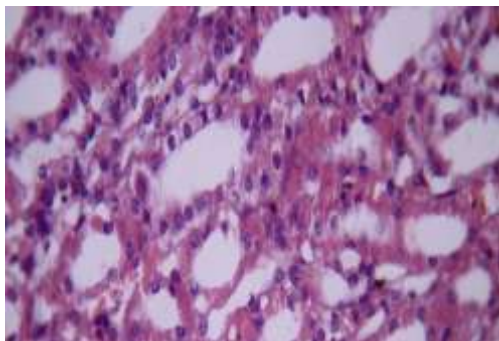


Fig 1. Group T₁ show normal kidney (power 200x).

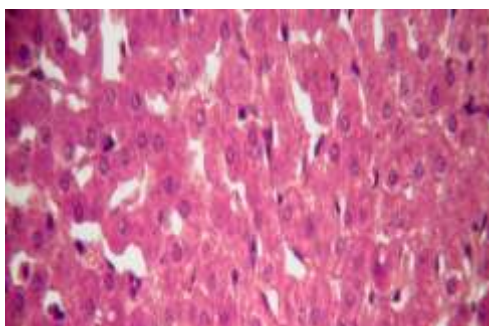


Fig. 2. Group T₁ show normal liver (200x)

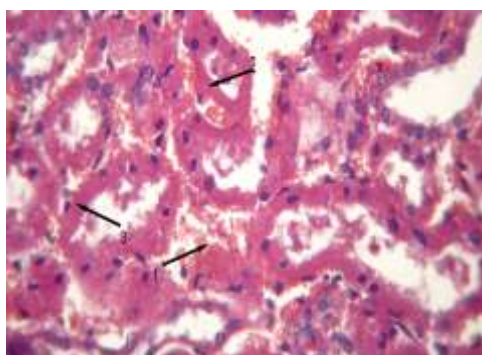


Fig.3. Group T₂ show kidney (200x). . In view arrow 1 indicates mild degenerative changes with intertubular vessel, arrow 2 indicates granular cytoplasm of the epithelial cells in proximal convoluted tubule (PCT) and arrow 3 indicates granular cytoplasm of the epithelial cells in distal convoluted tubule (DCT) of kidney.

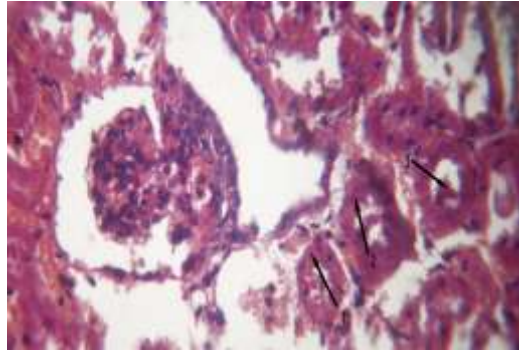


Fig. 4. Group T₂ show kidney (200x) . In view arrow 1 indicates cloudy swelling in proximal convoluted tubule (PCT), arrow 2 indicates cloudy swelling in distal convoluted tubule (DCT) and arrow 3 indicates albuminous mass of kidney.

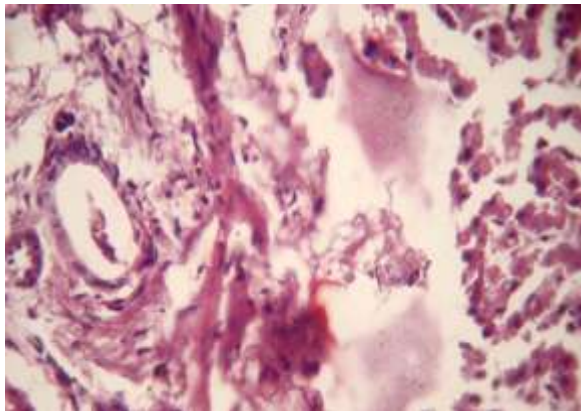


Fig. 5. Group T₂ showa clear Oedematous swelling in parenchyma of liver (200x)

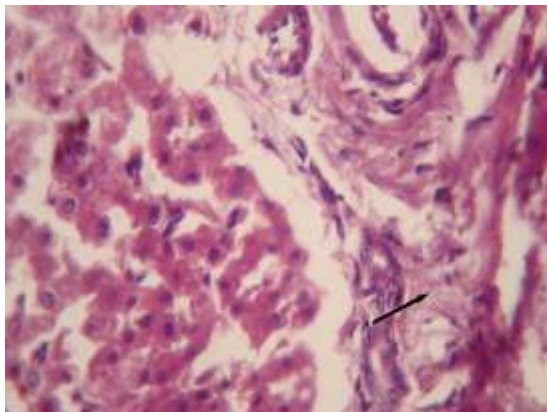


Fig. 6. Group T₂ show liver (200x) In view, Arrow 1 indicates proliferation of fibrous tissue in periportal area of liver.

DISCUSSION

The chemical composition of the diet is presented in Table 3 and the fiber component and minerals composition of the diet is given in Table 4. There was hypoxic injury to the cell due to increase absorption of ammonia from the rumen. A normal cell possesses a high intracellular osmotic colloidal pressure, exerted by a greater intracellular than extracellular concentration of protein. To balance the osmotic colloidal pressure, sodium is maintained at a lower intracellular than extracellular concentration by an energy-dependent sodium pump, that is, Na⁺, K⁺ ATPase. This pump also keeps the concentration of potassium significantly higher inside the cell than outside. The diminished ATPase, following acute hypoxia, affect the sodium pump, which then fails to regulate the active transport of ions. This results in the accumulation of sodium inside the cell, and diffusion of potassium out of the cell (Vegad, 1996). Mitochondrion plays an important role in maintaining hepatocyte integrity and function, which may be hampered due to excessive physiologic stress (Hassanein, 2004). Activity of AST is high in acute and chronic liver injury (Tennant, 1997). Significant increase in serum AST activity in UMMB treated kids suggests an increased respiratory burst and mitochondrial involvement, as AST is chiefly a mitochondrial enzyme. Elevation in the AST can also be associated with cell necrosis of many tissues. Pathology involving the skeletal or cardiac muscle and/or the hepatic parenchyma, allows the leakage of large amount of this enzyme into the blood (Kaneko, 1980). The elevation in AST is produced by the acetamiprid as an indication of wide spread tissue damage. Alanine amino transferase is a key cytoplasmic enzyme present in liver and other cells. It is particularly useful in measuring hepatic necrosis, especially in small animals (Cornelius, 1989). Alanine amino transferase is employed as a marker of hepato cellular damage and in general ALT is considered a more sensitive indicator of liver cell injury than AST (Cohn and Kaplan, 1971 and Oser, 1976). Though AST and ALT are not known to have any function in the plasma, but their increased level in the blood indicate cellular damage and increased membrane permeability (Ramazzotto and Carlin, 1978) and their altered metabolism (Dinman *et al.*, 1963). Since ALT is one of the specific assayable liver enzymes, its elevated level in the study may indicate hepatic damage caused by oral administration of UMMB. Although it is difficult to point the damage to any particular organ by UMMB, but increased levels of aminotransferases in rats may be attributed to liver damage, as it is the primary organ of biotransformation of UMMB.

VETRINARY & DISEASES

Kidney

Cloudy swelling in proximal convulated tubules (PCT) and distal convulated tubules (DCT) may be due to hypoxic insult to the cell, sodium-potassium balance was hampered and automatically sodium came inside the cell with water leading to swelling of the cell. Albuminous mass was also present in PCT and DCT (Fig. 4). Chronic injury to the epithelium leads to increase in $\text{PGF}_{2\alpha}$ through cAMP that increases the secretion of mucous in the lumen of the tubule which was stained with acidophilic stain (eosin).

Liver

On histopathological observation proliferation of fibrious tissue in periportal area was observed (Fig. 6). Uremia causes necrosis to the hepatocytes and chronic irritation of ammonia causes stimulation to the supportive tissue like fibrious tissue which was stained with basophilic stain. Due to anoxic condition the cyto skeletal activity causes altered cell size and interstitial space were increased. This increased space in-between the endothelial cells results in increase of vascular permeability. This leads to escape of the fluid from vasculature in parenchyma with proteinous substance, which leads to accumulation of serous fluid causing oedema (Vegad, 1996).

CONCLUSION

From the above experiment it could be concluded that overfeeding of UMMB may cause toxicity which may affect the organs.

REFERENCES

- AOAC. 1995. Official Methods of Analysis. 16th edn. Association of Official Analytical Chemists, Washington, D.C.
- Bloomfield, R. A., Garner, G. B. and Muher, M. E. 1960. Kinetics of urea metabolism in sheep (Abstr.). J. Anim. Sci. 19: 1248.
- Buck, W.B., Oaweler, G.D. and Van Gelder, G.A. 1973. Clinical and Diagnostic Veterinary Toxicology. Dubuque, Iowa: Kendall/ Hunt.
- Clarke, E.G.C., and Clarke, M.L. 1967. Garner's Veterinary Toxicology, 3rd ed. Baltimore: Williams and Wilkins.
- Cohn, C. and Kaplan, A. 1971. Clinical blood chemistry. In: Textbook of clinical pathology, 8th edn. (Eds: Miller, S. E. and Weller, J.M.) The Williams and Wilkins Company, Bultimore, USA. pp. 235-280.

**3rd International Scientific Conference on Small Ruminant Development, Hurghada,
Egypt, 12-15 April, 2010**

- Cornelius, C. E. 1989. Liver function. In: Clinical Biochemistry of Domestic animals. (Ed: Kaneko, J. J.). Academic Press Inc. San Diego. pp. 364-397.
- Dinman, B. D., Hamdi, E. A., Fox, C. F. and Frazola, W. J. 1963. Carbon tetra chloride toxicity: hepatostructural and enzymatic changes. Arch. Environ. Health. 7:630-646.
- Fiske, C. H. and Subba Rao, Y. 1925. In Oser, B.L. 1965. Hawk's physiological Chemistry. 14th Edn. McGrawHill Co, London. J. Biol. Chem. 66: 375.
- Hassanein, T. 2004. Mitochondrial dysfunction in liver disease and organ transplantation.
Mitochondrion 4: 609-620.
- Hooper, P.T. 1972. Spongy degeneration in the brain in relation to hepatic disease and ammonia toxicity in domestic animals. Vet. Rec. 90:37.
- Kaneko, J. J. 1980. Clinical biochemistry of domestic animals. 3rd Edn. Orlando, Fla, American Press.
- Oser, B. L. 1976. Hawk's physiological chemistry. McGraw – Hill Book Company, New York. London.
- Ramazzotto, L. J. and Carlin, R. 1978. Effects of DMSO on SGOT during hypothermia in adrenalectomized rats. Lifescience. 22: 329-336.
- Rekib, A. and D. P. Sadku. 1968. Effect of feeding higher doses of urea on the rumen metabolism in goat. Indian Vet. J. 45: 735-739.
- Singh, U. B. and Sulochona, S. 1997. Handbook of histological technique. Premier Publishing House, Kothi, Hyderabad.
- Snedecor, G. W. and Cochran, W. G. 1989. Statistical Methods. 8th edn. Iowa State University Press, Ames, Iowa.
- Tennant, B. C. 1997. Hepatic function in clinical biochemistry in domestic animal. 5th Edn. (Eds : Kaneko, J. J., Harvey, J. W. and Bruss, M. L.) Academic Press, San Diego. pp. 327-352.
- Van Soest P. J., Robertson J. B. and Lewis, B. A. 1991. Methods for dietary fibre, neutral detergent fibre and non-starch polysaccharides in relation to animal nutrition. Journal of Dairy Science. 74: 3583-3597.
- Vegad, J. L. 1996. A textbook of Veterinary General Pathology. Vikas Publishing House, Pvt. Ltd. New Delhi.

دراسة السمية دون المزمنة لقوالب المولاس المزودة باليوربا في صغار الماعز

إس.بي. تيوارى، أنجان روي، ساميران موندال^١ و إم.كيه. جيندلي

قسم تغذية الحيوان،^١ قسم علم الأمراض البيطرية، كلية العلوم
البيطرية وتربية الحيوان، أنجورا، درغ- ٤٩١٠٠١ تشاتيس جاره الهند

تم إجراء هذه التجربة لتقييم تأثيرات المكملات الغذائية لقوالب المولاس المعدنية المزودة باليوربا (UMMB) على السمية دون المزمنة في صغار الماعز الموجودة بالبلد. تم اختيار عشرين ماعز صغيرة نامية عشوائيًا ليتم إعطائها قش الأرز إلى حد الشع ودريس البرسيم (*Trifolium alexandrinum L.*) (٤٠:٦٠). تم تغذية المجموعة الأولى خليط مركز (٠.١ كجم/يومياً). تم تكملة غذاء المجموعة الثانية بقوالب المولاس المعدنية اليوربا (٠.٢ كجم/يومياً). استمرت التجربة لمدة ٩٠ يوماً. كان هناك انخفاضاً كبيراً (ب > ٠.٠٥) في نسبة الصوديوم في المصل (٦٠.٦٨ ملي مكافئ/لتر) وزيادة في نشاط ناقلة أمين الأستراتات (٣٤٠.٤٢ يو/إل) وفي ناقلة أمين الألانين (١٦٤.٩٦ يو/إل) الذي تم ملاحظته في صغار المجموعة الثانية مقارنة (بالمجموعة الأولى). عند إجراء الفحص الهيستوباثولوجي تمت ملاحظة تغييرات تنكسية طفيفة في كلية المجموعة الثانية مع احتقان في الأوعية بين النيبات، ووجود سيتوبلازم حبيبية للخلايا الظهارية في الأنابيب الملتفة القريبة (PCT) والأنابيب الملتفة البعيدة (DCT)، نخر وتضخم في الخلايا الظهارية، احتقان في الأوعية وتضخم غير واضح في الأنابيب الملتفة القريبة والأنابيب الملتفة البعيدة. لوحظ أيضاً وجود كتلة ألبومينية في القنيات. عند الملاحظة الهيستوباثولوجية لكبد صغار المجموعة الثانية لوحظ انتفاخ في النسيج الحشوي للكبد وتكاثر في النسيج الليفي في المنطقة المحيطة بوريد الباب.

